

# Ankylosing Spondylitis Treated with Phototherapy

Jose M. Calderon<sup>1\*</sup>, Jesus O. Garcia<sup>1</sup>, Irma G. Sanchez<sup>1</sup>, Cristian F. Tovar<sup>2</sup>, and Hugo M Zeron<sup>1,3</sup>

<sup>1</sup>Maternal-Perinatal Hospital "Monica Pretelini Saenz" (HMPMPS), Health Institute of the State of Mexico (ISEM), Toluca, Mexico

<sup>2</sup>Coordinacion de Hospitales de Alta Especialidad (CHAE), Secretaria de Salud, Toluca, Mexico

<sup>3</sup>Autonomous University of the State of Mexico (UAEMex) and Cipres Grupo Medico S.C. (CGM), Toluca, Mexico

**Received Date:** December 19, 2016, **Accepted Date:** January 27, 2017, **Published Date:** February 03, 2017.

**\*Corresponding author:** Jose Meneses Calderon, Maternal-Perinatal Hospital "Monica Pretelini Saenz", Health Institute of the State of Mexico (ISEM), Paseo Tollocan s/n. Col. La Moderna. C.P. 50120. Toluca, Mexico, Tel: 527-222-765-540; E-mail: [uci20042000@yahoo.com.mx](mailto:uci20042000@yahoo.com.mx).

## Abstract

Ankylosing spondylitis is a chronic rheumatic disease that affects the spine and sacroiliac joints, causing pain and inflammation. We presented a case of a 61 years old male with ankylosing spondylitis that, despite being receiving Nonsteroidal anti-inflammatory drugs (NSAIDs), analgesics and prednisone showed clinical deterioration. The patient received phototherapy within a range from 425 to 650 nm and a cytokine profile was measured at previous to the therapy and after 48 sessions. The clinical improvement was evident with pain remission and mobility recovery, as well as reduction in the proinflammatory cytokine profile.

**Keywords:** Ankylosing Spondylitis; Cytokines; Phototherapy

## Abbreviations

ABP: Arterial Blood Pressure; AS: Ankylosing Spondylitis; BASDAI: Bath Ankylosing Spondylitis Disease Activity Index; BMI: Body Mass Index; CFE: Federal Company of Electricity; CGM: Cipres Grupo Medico S.C.; COPD: Chronic Obstructive Pulmonary Disease; CRF: Chronic Renal Failure; DMARDs: Disease-Modifying Antirheumatic Drugs; GM-CSF: Granulocyte Macrophage Colony Stimulating Factor; HTA: Arterial Hypertension; IL: Interleukin; INF- $\gamma$ : Interferon- $\gamma$ ; MCAF: Monocyte Chemotactic and Activating Factor; NSAIDs: Nonsteroidal Anti-Inflammatory Drugs; OD: Optical Density; TNF- $\alpha$ : Tumor Necrosis Factor- $\alpha$ ; T2DM: Type 2 Diabetes Mellitus; UTI: Urinary Tract Infections.

## Introduction

Ankylosing Spondylitis (AS) is a chronic rheumatic disease that affects the spine and sacroiliac joints, causing pain and inflammation. Its global prevalence is between 0.1 and 1.4%, and patients with active disease may present diminished physical functioning due to the loss of lumbar mobility [1]. Nonsteroidal anti-inflammatory drugs (NSAIDs) and Coxibs remain important therapeutic options for AS, but since the last decade onwards, in developed countries, the use of biologic and synthetic Disease-Modifying AntiRheumatic Drugs (DMARD) and tumour necrosis factor inhibitors (TNFi) has been increased significantly; on the contrary, the use of steroids has been decreased [2-3]. On the other hand, different types of phototherapies, varying widely in the range of nanometers applied, have been used in clinical practice against autoimmune diseases [4-6]. Despite, its well known clinical benefit, there is scarce information regarding non UV phototherapy. In this line, our group has proved the benefit of this therapy against Rheumatoid Arthritis [7]. Looking for cheaper and efficient options against autoimmune diseases, the aim of this paper was to report a case of AS with clinical improvement after phototherapy treatment with the documentation of changes in the cytokine profile.

## Clinical Case

### Male of 61 years

**Familial antecedents:** The patient's 83-year-old mother had Chronic Obstructive Pulmonary Disease (COPD) associated with exposure to wood smoke, in addition to Type 2 Diabetes Mellitus (T2DM) and Arterial Hyper Tension (AHT) for 20 years, who had undergone right supracondylar amputation three years ago, with Chronic Renal Failure (CRF) and retinopathy, under medical management. The patient's father had died 30 years ago at the age of 71 years after underwent a surgery for right kidney tumor. The patient's three siblings aged 47, 56, and 65 years have T2DM. He has three apparently healthy children aged 32, 30, and 29 years.

**Personal non-pathological information:** Schooling: 6<sup>th</sup> grade; Occupation: Employee at the Federal Electricity Company (CFE) from the age of 18 years, working in the maintenance and repair of energized lines. The patient frequently received 150-200 volt electric shocks in the job for 20 years, always working with protective equipment. Smoking denied. Positive alcoholism from the age of 23 until 35 years, with alcohol ingestion once a month, consuming tequila or brandy (100-200 mL). Drug addictions denied. Complete immunization scheme in childhood. Application of influenza vaccine every two years.

**Personal pathological data:** Uncomplicated measles and childhood infectious diseases. From the age of 18-20 years, repetitive events of sore throat, odynophagia, cough, expectoration, and chills without fever remained up to three weeks, predominating in the period from December to January. Left inguinal hernia after physical activity at the age of 19 years, with no complications. Left wrist fracture at the age of 52 years without complications. Four Urinary Tract Infections (UTI) since the age of 40 years, past from three years, always receiving medical management for up to one and one half months with oral antibiotics not specified by the patient. Allergies and transfusions denied.

**Current disease:** From May 1994, the patient initiated with the disease at age of 40 years, when he presented intermittent pain in the lumbar region of mild intensity 2-3/10, of daily presentation, from the time of he gets up in the morning. He went to a general practitioner who referred him to second-level medical attention, where he was prescribed naproxen-type medications and other analgesics, which he took continuously, as well as daily physical exercise for rehabilitation purposes. Lumbar pain increased in intensity during the winter season to 5-6/10 with difficulty in bending.

In 2001, cervical pain 5-6/10 was added, with progressive intensity and with difficulty in turning over to the side, which increased until the patient was totally disabled for five years. From 2006, he was required to perform neck movements en bloc. After the onset of cervical pain, his family physician referred him to a

Rheumatologist who, after performing laboratory tests including HLA-B27 and X-rays, confirmed the diagnosis of AS. Management was begun with NSAID, analgesics and Prednisone, the patient taking the latter for 3–4 months. Pain increased in the lumbar region to 8/10, which forced the patient to walk in a semi-flexed posture, this was last for a period of one year. Pain intensity subsequently decreased to 3/10, remaining under these conditions until 10 years previously, when the patient stopped taking his medication for apparent remission of pain; the patient felt good, without discomfort. For the past 10 years, the patient has reported paresthesias in the outer half of the fourth finger and of the entire right hand (ulnar affection), extending to the middle third of the palmar region.

In 2016, patient referred pain in the right shoulder 8/10, right back, and right thorax 6–7/10, right elbow 6/10, which produced severe limitation for mobility of the upper right limb, with the inability to perform personal tasks such as eating or bathing. In addition, there was shoulder and right elbow flogosis with inflammation of the affected back and chest. Since April 7, 2016, the patient received, from a general practitioner, Diclofenac-Cholestyramine 75 mg p.o. every 12 h, thus reducing pain, flushing, and inflammation of the chest and back by about 50%, but after two months, due to physical limitation and pain, the patient was invited to receive phototherapy sessions.

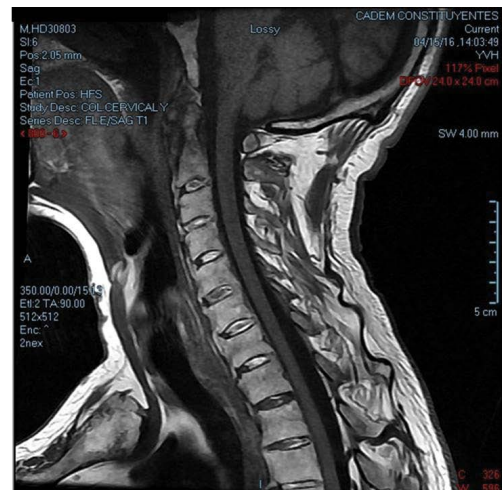
### Physical exploration

Arterial Blood Pressure (ABP): 122/80; heart rate: 70 x'; respiratory rate: 14 x'; temperature: 36°C, weight: 91 kg; height: 1.73 m; Body Mass Index (BMI): 30.4, and capillary glucose: 125 mg/dL.

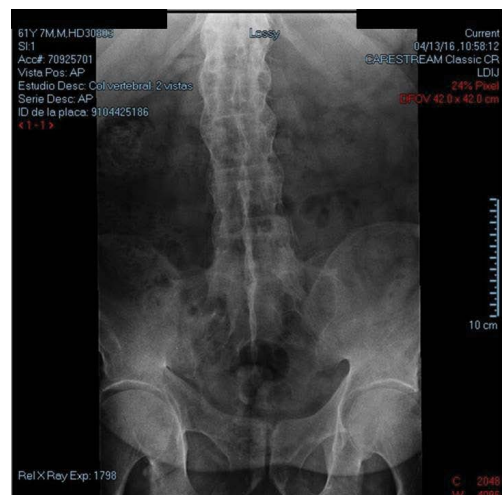
The patient experienced painful facies when attempting to mobilize neck and right upper limb, both of these with severe inability to perform minimal movements. Normal brain cerebral functions. Eyes with bilateral pterygium with conjunctival congestion ++, without secretion. Fundoscopy with angiosclerotic angiopathy without alterations in the retina. Neck: severe limitation on attempting lateral as well as flexion and extension movements. Mild jugular engorgement. Thyroid not palpable. Thorax: severe pain on palpation of the infrahumeral region, especially the pectoral musculature, which is perceived on touch with slight induration. Precordial area with rhythmic heart sounds, no blows or gallop. Soft abdomen, depressible, with normoperistalsis without hepatosplenomegaly. Extremities without edema. Joint exploration demonstrated mild-to-moderate spontaneous pain to pressure in the right shoulder with severe functional limitation in its arches of mobility. Mild pain on mobilization of right elbow. Prehension force: right hand: 300 mmHg; left hand: 300 mmHg. Imaging studies revealed cervical column affection (Figure 1), the characteristic "bamboo spine" (Figure 2), and right shoulder lesion (Figure 3).

### Intervention

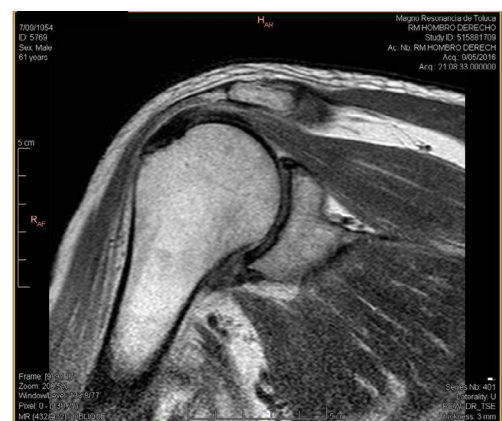This intervention was approved by the Ethics Committee of the Maternal-Perinatal Hospital "Monica Pretelini Saenz" (HMPMPS), code: 217B500402017001. Briefly, with the patient in supine position and placing the lamp 30 cm above the neck, the patient received phototherapy within a range from 425–650 nm (visible light spectrum) (Figure 4), 11.33 Joules/cm<sup>2</sup> (Phototherapy lamp, Federal Ministry of Health registration number 1694E95). The phototherapy scheme was 30 min, three times a week.



**Figure 1:** T1, sagittal section. Intervertebral bony bridges at all cervical levels.



**Figure 2:** Characteristic "bamboo" spine.



**Figure 3:** MRI, coronal section of the right shoulder. Partial rupture of the supraspinatus tendon.




Figure 4: Illustrative image of the lamp.

### Cytokine Expression

Granulocyte Macrophage Colony Stimulating Factor (GM-CSF), Interferon- $\gamma$  (INF- $\gamma$ ), Interleukin-4 (IL-4), IL-6, IL-10, IL-12, Monocyte Chemotactic and Activating Factor (MCAF), and Tumor Necrosis Factor alpha (TNF- $\alpha$ ) (Multiplex Human Cytokine ELISA Kit) were determined with the Optical Density (OD) value method by means of the Enzyme-Linked Immunosorbent Assay (ELISA) at 490 nm employing ELx800™ equipment (BioTek Instruments, Inc., USA). The process was conducted in blinded fashion at the Research Laboratory of CipresGrupoMedico S.C. (CGM), Toluca, State of Mexico, Mexico.

### Evolution

After phototherapy sessions, the patient’s clinical improvement was notorious. The Bath Ankylosing Spondylitis Disease Activity Index (BASDAI) and the Bath Ankylosing Spondylitis Functional Index (BASFI) showed impressive changes, the first from 100 to 0 points and the second from 98 to 6 after the 48 sessions. The Ankylosing Spondylitis Quality of Life Questionnaire (ASQoL) changed from 15 to 1. The latter evaluations happened in addition to the reduction in the inflammatory profile (GM-CSF, MCAF, TNF- $\alpha$ ) and vice versa with that of the anti-inflammatory cytokines (IL-4, IL-10). IL-12 was practically without changes (Table 1).

Cytokine	Basal	After 48 sessions
GM-CSF (ng / mL)	5.854	0.735
INF- $\gamma$ (ng / mL)	33.192	67.611
IL-4 (ng / mL)	8.768	28.872
IL-6 (ng / mL)	15.534	4.108
IL-10 (ng / mL)	35.516	39.634
IL-12 (ng / mL)	12.209	12.209
MCAF (ng / mL)	213.187	195.698
TNF- $\alpha$ (ng / mL)	14.3204	5.357

**Table 1:** Cytokine evolution. (GM-CSF: Granulocyte Macrophage Colony Stimulating Factor, IL: Interleukin, INF- $\gamma$ : Interferon-gamma, MCAF: Monocyte Chemotactic and Activating Factor, TNF- $\alpha$ : Tumor Necrosis Factor-alfa)

Modality of phototherapy	Diseases
Extracorporeal photopheresis [18,19]	Cutaneous T cell lymphoma, autoimmune and inflammatory diseases associated with proliferation of autoreactive T cells.
Intravenous laser irradiation [20]	Rheumatoid Arthritis
Far-infrared [21]	Cardiovascular and autoimmune diseases, diabetes mellitus, and chronic kidney disease.
Laser [22]	Autoimmune thyroid disease

**Table 2:** Modalities of phototherapy against autoimmune diseases.

### Discussion

At present, there are several pharmacological alternatives for treating AS. While the first is the use of NSAID, for those patients whose disease activity remains high despite the use of the former, anti-TNF drugs comprise second-line treatment. Other AS therapies include DMARD, such as Hydroxychloroquine, Methotrexate and Sulfasalazine, for patients with peripheral arthritis [8].

A limiting factor for the generalized use of anti-TNF is the cost, up to US \$1,182 per month per patient, of course with price disparities, being the lowest cost associated to the use of Etanercept, followed by Adalimumab and Infliximab [9]. When evaluating the disease activity, inflammation, lumbar pain and physical function, a two year randomized open trial reported no differences between Infliximab and Etanercept therapy [10]. In the case of the treatment that we offered to the patient, no cost to the patient was involved at our Institution. In case of the treatment being installed in the patient’s home, this could cost between US \$25 and US \$50 per month for a period of one year, adding the cost of the lamp and the electricity consumption.

Inflammation of the sacroiliac joint at the base of the spine, followed by rising inflammation along the spine are the principal features of AS that results in back pain and stiffness [11]. Although the use of NSAID, DMARD, and non-drug interventions such as physical therapy may offer palliation of symptoms, including peripheral joint pain, spinal pain, in addition to the improvement shown in the physical function [12,13], none has been shown to alter the progression of AS. In the case we reported, it was clear the clinical improvement with the phototherapy, the patient recovering the mobility of the lumbar and cervical column. We anticipate that our findings will produce reasonable doubts in the rheumatological field. Thus, the medical patient file and a possible in vivo online contact with the patient and authors are available upon request.

It is certain that targeted biologic therapies have revolutionized the clinical management of AS. In this line, clinical trials have shown that these agents produce clinically important benefits to patients by improving physical functioning and reducing disease activity [14]. A previous meta-analysis synthesized the data on different agents and concluded that TNF- $\alpha$  blockers improve disease activity and functional capacity in AS [15,16]. Based on our previous reports of the effect of phototherapy on autoimmune diseases [7,17], we think that this therapy reduces TNF- $\alpha$  levels by still unknown mechanisms, probably changing the Th1/Th2 lymphocyte ratio.

It is recognized that the action of phototherapy over autoimmune diseases is effective, with several modalities (Table 2). Notwithstanding, we think the feasibility of our technique offers a new opportunity to reach a clinical improvement at low cost.

### Conclusion

Phototherapy within a range of 425–650 nm was effective in this case of AS for the recovery of mobility and for pain reduction, which offers a new window for exploration and a new, inexpensive alternative for treatment of this disease. The mechanism of action appears to be the reduction of TNF- $\alpha$  levels.



## Acknowledgements

Authors thank Maria Isabel Ospina and Isaac M. Lepinky Torres for their help to process the samples and Maggie Brunner M.A. for her excellent help with the English style correction.

## Declaration

The authors declare that they have no conflict of interests.

## References

- Machado MA, Ferre F, Moura CS, Almeida AM, Andrade EI, Cherchiglia ML, et al. Costs of Drug Therapy in Patients with Ankylosing Spondylitis in Brazil. *Rheumatol Ther*. 2016;3(2):353-361.
- Huscher D, Rudwaleit M, Thiele K, Bischoff S, Kotter I, Fischer K, et al. SAT0447 Changes in treatment and outcomes of ankylosing spondylitis in routine care in Germany 2000 to 2010. *Ann Rheum Dis*. 2013;71(3):623. doi:10.1136/annrheumdis-2012-eular.3393.
- Huscher D, Thiele K, Rudwaleit M, Albrecht KC, Bischoff S, Krause A, et al. Trends in treatment and outcomes of ankylosing spondylitis in outpatient rheumatological care in Germany between 2000 and 2012. *RMD Open*. 2015;1(1). doi:10.1136/rmdopen-2014-000033.
- Lehmann P. [Phototherapy in the era of biologicals]. *Hautarzt*. 2013;64(5):345-8. doi: 10.1007/s00105-012-2511-z.
- Breuer J, Schwab N, Schneider-Hohendorf T, Marziniak M, Mohan H, Bhatia U, et al. Ultraviolet B light attenuates the systemic immune response in central nervous system autoimmunity. *Ann Neurol*. 2014;75(5):739-58. doi: 10.1002/ana.24165.
- Abreu ACG, Duarte GG, Miranda JY, Ramos DG, Ramos CG, Ramos MG. Immunological Parameters Associated With Vitiligo Treatments: A Literature Review Based on Clinical Studies. *Autoimmune Dis*. 2015; doi.org/10.1155/2015/196537.
- Meneses Calderon J, Gonzalez Sanchez I, Aburto Huacuz G, Alonso Barreto AS, Del Carmen Colin Ferreyra M, Mendieta Zeron H. Trends of inflammatory markers and cytokines after one month of phototherapy in patients with rheumatoid arthritis. *Acta Med Acad*. 2015;44(2):102-8. doi: 10.5644/ama2006-124.137.
- Braun J, van den Berg R, Baraliakos X, Boehm H, Burgos-Vargas R, Collantes-Estevez E, et al. 2010 update of the ASAS/EULAR recommendations for the management of ankylosing spondylitis. *Ann Rheum Dis*. 2011;70(6):896-904. doi:10.1136/ard.2011.151027.
- Azevedo VF, Rossetto CN, Lorencetti PG, Tramontin MY, Fornazari B, Araujo DV. Indirect and direct costs of treating patients with ankylosing spondylitis in the Brazilian public health system. *Rev Bras Reumatol Engl Ed*. 2016;56(2):131-7. doi: 10.1016/j.rbre.2015.08.009.
- Giardina AR, Ferrante A, Ciccia F, Impastato R, Miceli MC, Principato A, et al. A 2-year comparative open label randomized study of efficacy and safety of etanercept and infliximab in patients with ankylosing spondylitis. *Rheumatol Int*. 2010;30(11):1437-40. doi: 10.1007/s00296-009-1157-3.
- Dakwar E, Reddy J, Vale FL, Uribe JS. A review of the pathogenesis of ankylosing spondylitis. *Neurosurg Focus*. 2008;24(1):E2. doi: 10.3171/FOC/2008/24/1/E2.
- Corli J, Flipo R-M, Philippe P, Bera-Louville A, Behal H, Wibaux C, et al. Tumor Necrosis Factor- $\alpha$  Inhibition in Ankylosing Spondylitis and Non radiographic Axial Spondyloarthritis: Treatment Response, Drug Survival, and Patient Outcome. *Ann Rheum Dis*. 2015;74:273 doi:10.1136/annrheumdis-2015-eular.2156.
- Maxwell LJ, Zochling J, Boonen A, Singh JA, Veras MMS, Tanjong Ghogomu E, et al. TNF-alpha inhibitors for ankylosing spondylitis. *Cochrane Database Syst Rev*. 2015;1(4):CD005468.
- McLeod C, Bagust A, Boland A, Dagenais P, Dickson R, Dunder Y, et al. Adalimumab, etanercept and infliximab for the treatment of ankylosing spondylitis: a systematic review and economic evaluation. *Health Technol Assess*. 2007;11(28):1-158, iii-iv.
- Callhoff J, Sieper J, Weib A, Zink A, Listing J. Efficacy of TNF $\alpha$  blockers in patients with ankylosing spondylitis and non-radiographic axial spondyloarthritis: a meta-analysis. *Ann Rheum Dis*. 2015 Jun;74(6):1241-8. doi: 10.1136/annrheumdis-2014-205322.
- Ward MM, Deodhar A, Akl EA, Lui A, Ermann J, Gensler LS, et al. American College of Rheumatology/Spondylitis Association of America/Spondyloarthritis Research and Treatment Network 2015 Recommendations for the Treatment of Ankylosing Spondylitis and Nonradiographic Axial Spondyloarthritis. *Arthritis Rheumatol*. 2016;68(2):282-98. doi: 10.1002/art.39298.
- Calderon JM, Huacuz GA, Sanchez IG, Vilchis AG, Zeron HM. Phototherapy Induces an Improvement In Clinical and Biochemical Scores In Rheumatoid Arthritis. *West Indian Med J*. 2016; doi:10.7727/wimj.2015.490.
- Adamski J, Kinard T, Ipe T, Cooling L. Extracorporeal photopheresis for the treatment of autoimmune diseases. *Transfus Apher Sci*. 2015;52(2):171-82. doi: 10.1016/j.transci.2015.02.005.
- Just U, Knobler R. [Update on extracorporeal photopheresis]. *Hautarzt*. 2015;66(11):804-9. doi: 10.1007/s00105-015-3702-1.
- Burduli NN, Burduli NM. [The influence of intravenous laser irradiation of the blood on the dynamics of leptin levels and the quality of life of the patients presenting with rheumatoid arthritis]. *Vopr Kurortol Fizioter Lech Fiz Kult*. 2015;92(3):11-3.
- Shui S, Wang X, Chiang JY, Zheng L. Far-infrared therapy for cardiovascular, autoimmune, and other chronic health problems: A systematic review. *Exp Biol Med (Maywood)*. 2015;240(10):1257-65. doi: 10.1177/1535370215573391.
- Hofling DB, Chavantes MC, Acencio MMP, Cerri GG, Marui S, Yoshimura EM, et al. Effects of low-level laser therapy on the serum TGF- $\beta$ 1 concentrations in individuals with autoimmune thyroiditis. *Photomed Laser Surg*. 2014;32(8):444-9. doi: 10.1089/pho.2014.3716.

\*Corresponding author: Jose Meneses Calderon, Maternal-Perinatal Hospital "Monica Pretelini Saenz", Health Institute of the State of Mexico (ISEM), Paseo Tollocan s/n. Col. La Moderna. C.P. 50120. Toluca, Mexico, Tel: 527-222-765-540; E-mail: [uci20042000@yahoo.com.mx](mailto:uci20042000@yahoo.com.mx).

Received Date: December 19, 2016, Accepted Date: January 27, 2017, Published Date: February 03, 2017.

Copyright: © 2017 Calderon JM, et al. This is an open access article distributed under the Creative Commons Attribution License, which permits unrestricted use, distribution, and reproduction in any medium, provided the original work is properly cited.

Citation: Calderon JM, Garcia JO, Sanchez IG, Tovar CF, Zeron HM (2017) Ankylosing Spondylitis Treated with Phototherapy. *J Alt Med Res* 3(1): 119.